

A Novel Application of Dermabrasion

Vijayaraghavan Nandhagopal*, Ravi Kumar Chittoria**, Devi Prasad Mohapatra***, Friji Meethale Thiruvoth***, Dinesh Kumar Shivakumar***, Arjun Ashokan*

*Resident **Head ***,****,*****Associate Professor, Department of Plastic Surgery, JIPMER, Pondicherry, India

Introduction

Dermabrasion, which was developed in the 1950s, mechanically abrades the epidermis and upper portion of the dermis[1]. The epidermis is entirely obliterated and there is partial removal of the dermis, which undergoes incomplete regeneration. It is a common procedure used by dermatologist and plastic surgeons. It is used for a variety of indications like acne scars, surgical scars, benign tumors, facial rejuvenation and many other uses[2]. Here we describe a novel use of dermabrasion.

Case Report

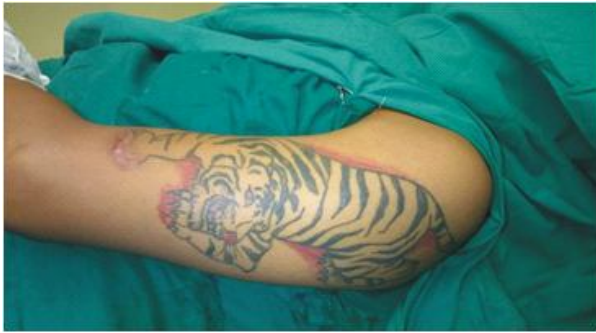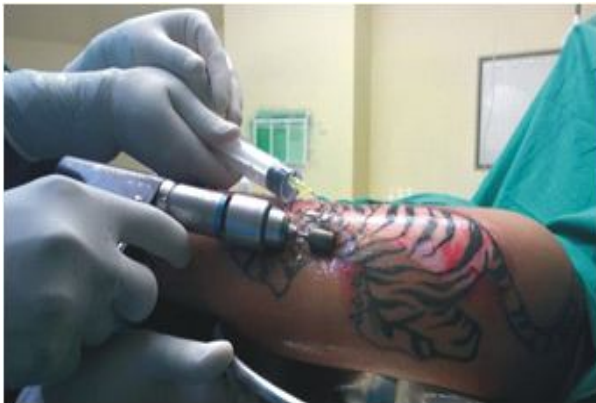
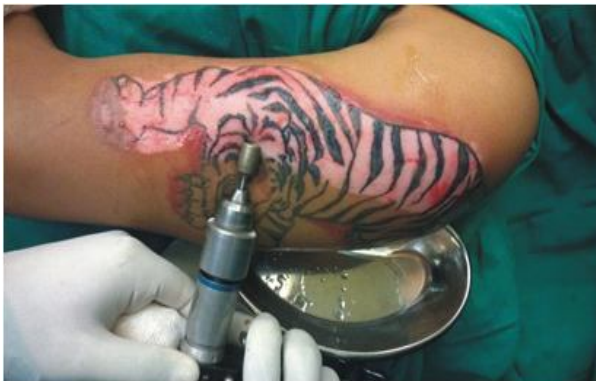We report a 26 year old male with a history of tattooing over left arm 1 year back(Fig 1). Patient now presented to OPD for tattoo removal. Patient was examined and the treatment options explained. Patient was planned for dermabrasion of the tattoo. Under tumescent anaesthesia, patient underwent dermabrasion of the tattoo using a power driven dermabrader with diamond tipped burr(Fig 2). Saline irrigation was used while dermabrading the skin. The dermabrased skin and the saline solution extract were collected using a kidney tray in a sterile fashion(Fig3). The dermabrased skin was resurfaced with split skin graft harvested from the right thigh. The dermabrased skin extract was applied to the raw area in the thigh(Fig4). The donor site was covered using a standard dressing. There were no

immediate post-operative complications. The donor site was opened at 7 days. The donor site had completely healed in 7 days(Fig5). Skin graft over the arm had complete take.

Fig. 1: Tattoo over left arm

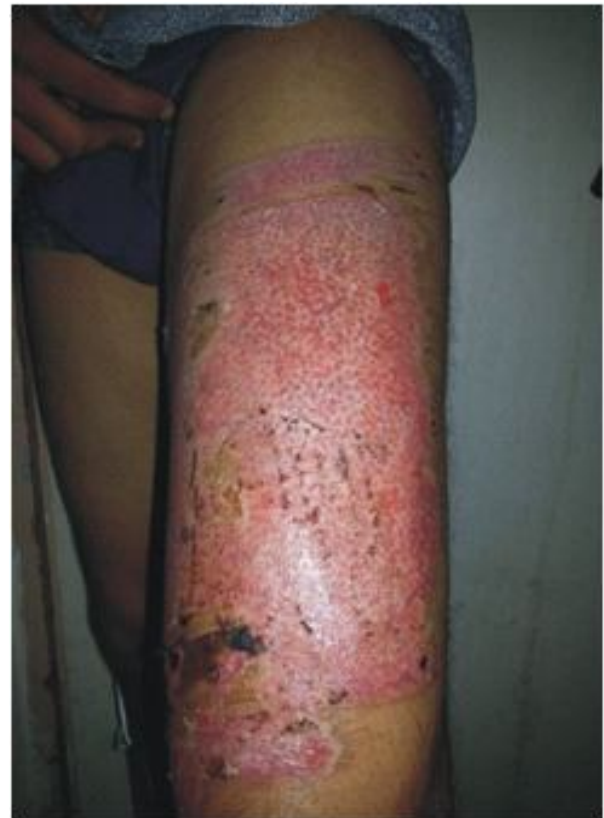
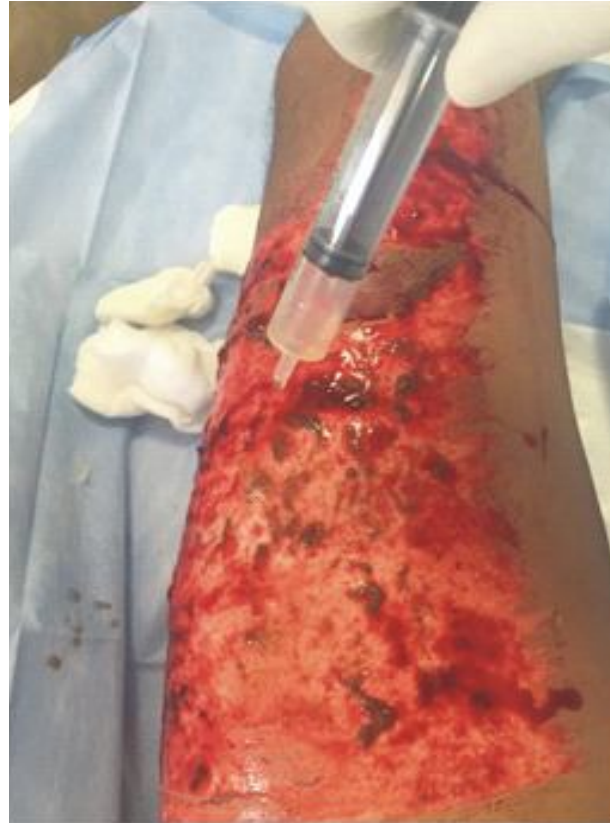
Corresponding Author: Ravi Kumar Chittoria,
Department of Plastic Surgery, 4th Floor, Super, Specialty
block, JIPMER, Gorimedu, Puducherry- 605006.
E-mail: drchittoria@yahoo.com

Fig. 2: Dermabrasion with diamond tip burr**Fig. 3:** Collection of dermabraded skin extract in a sterile kidney tray**Fig. 4:** dermabraded skin extract applied over the donor skin

Discussion

Dermabrasion is a simple, cost-effective means of skin resurfacing that can provide repeated and reliable results when used on the face or many other areas of the body. Numerous studies have demonstrated that dermabrasion is a reliable and effective method for skin resurfacing and should be a part of a plastic and dermatologic surgeon's repertoire in resurfacing damaged skin and the aging and damaged face.

Fig. 5: Healed donor site in 7 days

On review of literature we did not find any article demonstrating the use of dermabraded skin. We planned to study the use of the dermabraded skin extract. In accordance with the Gillies principle we decided not to discard any useful tissue. Usually the dermabraded skin is resurfaced with the application of split skin graft.

The donor site usually heals by epithelialisation from the skin appendages and the peripheral epithelialisation[3]. Many modalities have been described to expedite the donor site healing including grafting the donor site [4] when a dermabrasion is performed the dermabraded skin extract was harvested by us in a sterile manner. Since the extract contains mainly epidermal cells we applied it over the donor site and covered the donor site with standard dressing.

Wound healing was complete by seventh post operative day. The accelerated wound healing could have been by the supplementation of regular epithelialisation by the cellular content in the dermabraded extract.

This theory requires further analysis by a well designed controlled study with analysis of the dermabraded skin extract for cellular components.

Conclusion

The dermabraded skin extract collected in a sterile fashion can be applied to the skin graft donor site in the same patient for accelerating the rate of epithelialisation and promoting wound healing of the donor site.

References

1. Campbell RM, Harmon CB Dermabrasion in our practice *Journal of Drugs in Dermatology : JDD* 2008, 7(2): 124-128.
2. Baker TM. Dermabrasion. As a complement to aesthetic surgery. *Clin Plast Surg*. Jan 1998; 25 (1): 81-8.
3. Winter GD. Formation of the scab and the rate of epithelization of superficial wounds in the skin of the young domestic pig. *Nature*. 1962; 193: 293-294.
4. Chuenkongkaew T. Modification of split-thickness skin graft: cosmetic donor site and better recipient site. *Ann Plast Surg*. 2003; 50: 212-214.